

**The original documents are located in Box 37, folder “Ford, Gerald - Inenrval Six - Month Physical - August 22, 1974” of the Betty Ford White House Papers, 1973-1977 at the Gerald R. Ford Presidential Library.**

**Copyright Notice**

The copyright law of the United States (Title 17, United States Code) governs the making of photocopies or other reproductions of copyrighted material. Betty Ford donated to the United States of America her copyrights in all of her unpublished writings in National Archives collections. Works prepared by U.S. Government employees as part of their official duties are in the public domain. The copyrights to materials written by other individuals or organizations are presumed to remain with them. If you think any of the information displayed in the PDF is subject to a valid copyright claim, please contact the Gerald R. Ford Presidential Library.

**CLINICAL RECORD****NARRATIVE SUMMARY**

DATE OF ADMISSION

DATE OF DISCHARGE

NUMBER OF DAYS HOSPITALIZED

*(Sign and date at end of narrative)*

Physical Examination - Mr. Gerald R. Ford - 22 August 1974  
President of the United States

Age: 61 - Birth date - July 14, 1913

The President had his first interval physical examination since becoming President this morning. His current medical history indicates that he continues to enjoy good health and has had very few problems.

Problem #1 - Pain in the left cervical area. This discomfort occurs sporadically and is often related to the position in which he sleeps and fatigue. The discomfort may radiate pain in the left shoulder. There have been no associated radicular symptoms.

Problem #2 - Post-Surgical Knees - His previous history of surgery has been very successful. He will, however, after prolonged activity have minimal discomfort in the right knee which may cause him to have a slight limp. He denies any frank signs of effusion or inflammation.

Problem #3 - Weight Control - The President has been on a 1800 calorie diet and has since lost 10 pounds, starting from 210, and he now weighs 200 3/4.

The patient denies any symptoms pertaining to the cardiovascular system and has an excellent exercise tolerance. He has continued intermittent Atromid-S for a slight lipid abnormality, although recently he has not taken any of this medication.

There have been no digestive complaints and bowel movements have been regular with stool of normal consistency and no evidence of bleeding on the tissue.

He has had no recent problems related to his history of sinus congestion although at times he may sneeze and have a post-nasal drip.

Review of Systems:

*(Use additional sheets of this form (Standard Form 502) if more space is required)*

SIGNATURE OF PHYSICIAN	DATE	IDENTIFICATION NO.	ORGANIZATION
PATIENT'S IDENTIFICATION <small>(For typed or written entries give: Name—last, first, middle; grade; date; hospital or medical facility)</small>		REGISTER NO.	WARD NO.

FORD, Gerald R.  
372-28-6532

NARRATIVE SUMMARY  
Standard Form 502  
502-108



CLINICAL RECORD		NARRATIVE SUMMARY	
DATE OF ADMISSION	DATE OF DISCHARGE	NUMBER OF DAYS HOSPITALIZED	

(Sign and date at end of narrative)

Eyes - The President requires glasses for ~~close reading~~ *far vision* and has no other visual symptoms.

Ears - Nose and throat are normal.

Pulmonary - No difficulty with shortness of breath or cough.

Cardiovascular - Patient denies any exertional dyspnea, chest pain, palpitation or vascular difficulty.

Gastrointestinal - No difficulty with indigestion, abdominal discomfort, or unusual bowel movements.

Genitourinary - Nocturia one time per night with no urgency and no stress. Urine color is normal.

Neuromuscular - He has occasional pain in the left cervical area radiating to the left shoulder and he occasionally experiences slight discomfort in post-surgery right knee.

Neurological - He denies any headaches or problems related to the nervous system.

Skin - No skin lesions.

Physical Examination: Patient appears well nourished and robust. Blood pressure 120/80, pulse rate 58, temperature 98 degrees, height 72 inches, weight 200 3/4 pounds.

Eyes - Pupils are round, regular and react to light and accommodation. Extraocular movements normal. Ocular fundi normal.

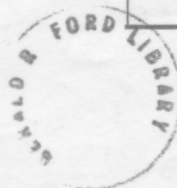
Ears - Normal external ear canals. Ear drums are normal.

Nose - Slight deviation of the nasal septum. The mucosa appears normal.

(Use additional sheets of this form (Standard Form 502) if more space is required)

SIGNATURE OF PHYSICIAN	DATE	IDENTIFICATION NO.	ORGANIZATION
PATIENT'S IDENTIFICATION (For typed or written entries give: Name—last, first, middle; grade; date; hospital or medical facility)		REGISTER NO.	WARD NO.

FORD, Gerald R.  
372-28-6532



NARRATIVE SUMMARY  
Standard Form 502  
502-108

CLINICAL RECORD		NARRATIVE SUMMARY	
DATE OF ADMISSION	DATE OF DISCHARGE	NUMBER OF DAYS HOSPITALIZED	

(Sign and date at end of narrative)

Mouth - Teeth are in good repair although there is dark tobacco staining. There is no mucosal abnormality involving his palate.

Neck - Neck is supple with good range of motion. Thyroid not enlarged. No lymph nodes. Carotid artery pulsations equal without bruit.

Breasts - Negative.

Lungs - Clear and resonant to percussion and auscultation.

Heart - No abnormal heart sounds. No murmurs or gallop sounds were heard. A2 normally split.

Abdomen - Soft and non-tender. No masses. Liver and spleen are not enlarged. Liver was 12 cm in the mid-clavicular line. Right appendix scar was intact. Inguinal rings were normal.

Rectal - Very small hemorrhoidal tags. Sphincter tone good. Prostate normal size, smooth, and non-tender. No feces were in the rectal ampulla.

External Genitalia - Normal male with normal sized testicles.

Neuromuscular Exam - Shoulder joints were completely normal with a good range of motion. The left knee was stable without inflammation and no swelling. The right knee appears somewhat larger than the left. There was some grating sensation on flexion. No tenderness was apparent. The range of motion was good. In both instances the quadriceps muscle strength was substantial. Examination of the feet revealed no abnormalities.


Neurological - All deep tendon reflexes are active and equal. No sensory abnormality noted.

The summary of the President's laboratory tests has indicated essentially normal blood counts and serum chemistries with the exception of a high normal uric acid of 8.8.

(Use additional sheets of this form (Standard Form 502) if more space is required)

SIGNATURE OF PHYSICIAN	DATE	IDENTIFICATION NO.	ORGANIZATION
PATIENT'S IDENTIFICATION (For typed or written entries give: Name—last, first, middle; grade; date; hospital or medical facility)		REGISTER NO.	WARD NO.

FORD, Gerald R.  
372-28-6532



NARRATIVE SUMMARY  
Standard Form 502  
502-108

CLINICAL RECORD		NARRATIVE SUMMARY	
DATE OF ADMISSION	DATE OF DISCHARGE	NUMBER OF DAYS HOSPITALIZED	

(Sign and date at end of narrative)

The high normal range is (2.5-8.0). The serum cholesterol was 260 with the normal range (150-300). The level of his serum tryglycerides was 165 and the abnormal is greater than 200. Total and pre-B tryglycerides are within normal limits. Electrophoretic pattern not accurate when Rx has been instituted (non-baseline). Values are within normal limits for age. The urine was normal. The electrocardiogram remains unchanged from his previous tracing and is considered entirely normal. Blood type is O Rh positive.

In summary, the President is in excellent health and the only recommendations will be to provide a diet of 1800 calories with the goal of reducing one or two pounds a week until he reaches 195 pounds. In addition, he will be instructed in an exercise physical conditioning program which will include graduated knee weights, bicycling, and simple calisthenics which will be performed in his study each morning. In addition, he will be encouraged to play golf and swim if his schedule will allow it.

It is anticipated that the President will have his complete annual physical in January at Bethesda Naval Hospital.

*W. M. Lukash*  
William M. Lukash, M.D.  
Rear Admiral, MC, USN  
Physician to the President



(Use additional sheets of this form (Standard Form 502) if more space is required)

SIGNATURE OF PHYSICIAN	DATE	IDENTIFICATION NO.	ORGANIZATION
PATIENT'S IDENTIFICATION (For typed or written entries give: Name—last, first, middle; grade; date; hospital or medical facility)		REGISTER NO.	WARD NO.

FORD, Gerald R.  
372-28-6532

NARRATIVE SUMMARY  
Standard Form 502  
502-108



111111 FORD, GERALD R.

00 372 28 6532 WH

8/30/74

\*\*\*\*\*

DATE 8/22 8/28


TEST NORMALS UNITS

LIPOPROTEIN	BLOOD	8/26
APPEARNC		CLEAR
CHOLESTL	MG%	260.0
TRIGLYC	MG%	165.0
PHENOTYP		NORMAL

T4	BLOOD	8/22
RESULT	5.1- 11.1 MCG%	7.4

\*\*\*\*\* PERMANENT REPORT - RETAIN ON CHART \*\*\*\*\*

*Dr. Lukash*



111111 FORD, GERALD R.

00 372 28 6532 WH

8/30/74

# PATIENT CUMULATIVE REPORT

111111 FORD, GERALD R.

00 372 28 6532 WH

8/22/74

\*\*\*\*\*

DATE 8/22

TEST NORMALS UNITS

SMA-12	BLOOD	(0828)	1
TOT PROT	6.0- 8.0	GM%	6.3
ALBUMIN	3.5- 5.0	GM%	4.3
CALCIUM	8.5- 10.5	MG%	9.1
PHOS	2.5- 4.5	MG%	3.9
CHOLEST	150.0-300.0	MG%	247.
BUN	10.0- 20.0	MG%	14.
URIC AC	2.5- 8.0	MG%	8.8 *
CREATNIN	.6- 1.4	MG%	1.6 *
TOT BILI	.2- 1.0	MG%	.7
ALK PHOS	30.0- 85.0	MU/ML	29. *
LDH	100.0-225.0	MU/ML	203.
SGOT	7.0- 40.0	MU/ML	*INVAL

SMA-6	BLOOD	(0828)	
CHLORIDE	95.0-105.0	MEQ/L	105.
CO2	24.0- 32.0	MEQ/L	25.2
POTASIU	3.5- 5.0	MEQ/L	4.3
SODIUM	135.0-145.0	MEQ/L	141.
BUN	10.0- 20.0	MG%	14.
GLUCOSE	65.0-110.0	MG%	130. *

*(Report FBS on 9/5/74 was 100 mgm/100)*

SGPT	BLOOD	(0828)	
RESULT	.0- 50.0 IU/L		8.

ESR	BLOOD	(0828)	
RESULT	.0- 20.0 MM/HR		10.

CBC-COULTER	BLOOD	(0828)	
WBC	5.0- 10.0	K/CMM	4.7 *
RBC	4.2- 5.4	M/CMM	4.61
HGB	12.0- 16.0	GM%	15.4
HCT	37.0- 47.0	VOL%	44.2
MCV	81.0- 99.0	CMI	96.
MCH	27.0- 31.0	MMG	33.2 *
MCHC	32.0- 36.0	%	34.7



111111 FORD, GERALD R.

00 372 28 6532 WH

8/22/74

# PATIENT CUMULATIVE REPORT

111111 FORD, GERALD R.

00 372 28 6532 WH

8/22/74

\*\*\*\*\*

DATE 8/22

TEST NORMALS UNITS

DIFFERENTIAL	BLOOD	(0828)
SEG	51.0- 67.0	% 58.
LYMPH	21.0- 35.0	% 39. *
MONO	4.0- 8.0	% 2. *
EOSIN	2.0- 4.0	% 1. *
PLATELTS	-	ADEQ

GROUP & TYPE	BLOOD	(0828)
RESULT		0 POS

\*\*\*\*\*

## COMMENTS

1 SMA-12 8/22 828 CREATININE AND URIC ACID CONFIRMED BY BENCH METHOD

1 SMA-12 8/22 828 CHANNEL DOWN, ~~RE ORDER IF CLINICALLY INDICATED~~

\*\*\*\*\* TEMPORARY REPORT - DISCARD WHEN NEXT REPORT IS RECEIVED \*\*\*\*\*

SCOT WILL RE RE RUN 8/23  
lyd



111111 FORD, GERALD R.

00 372 28 6532 WH

8/22/74

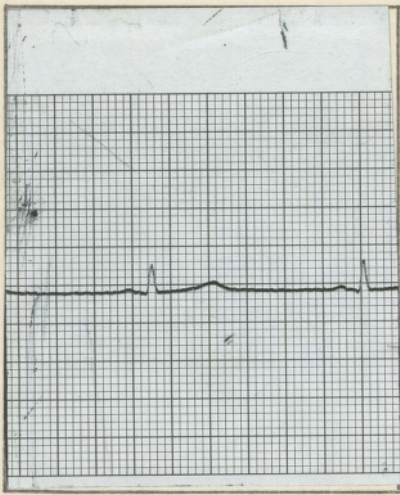


Step Father -  
died of Stroke  
age 72  
Father died age 59





1

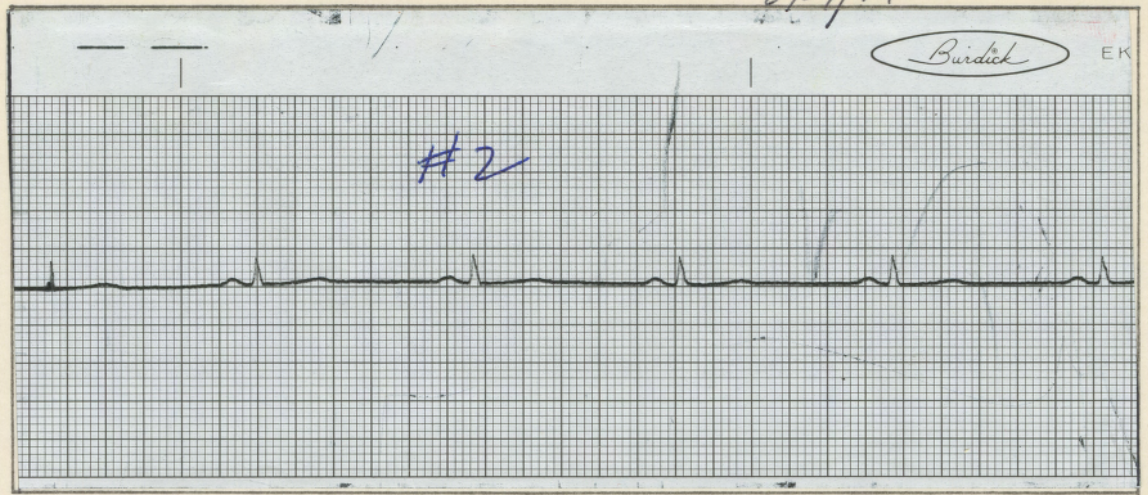


2

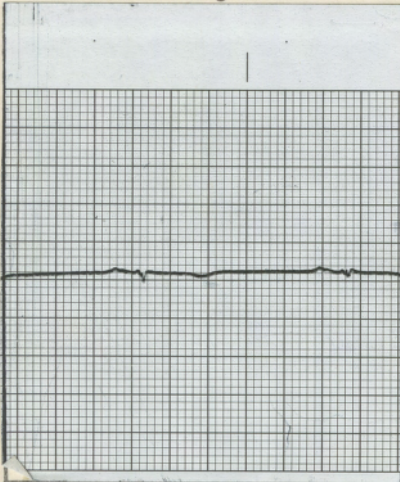
8/24/74

Burdick

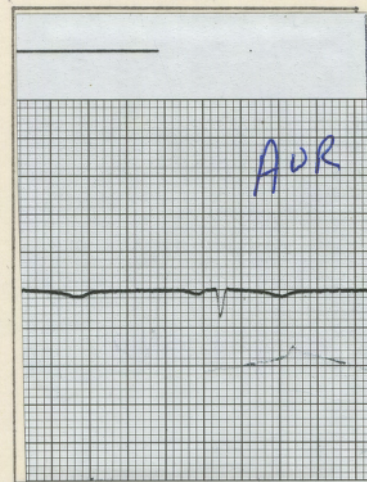
EK



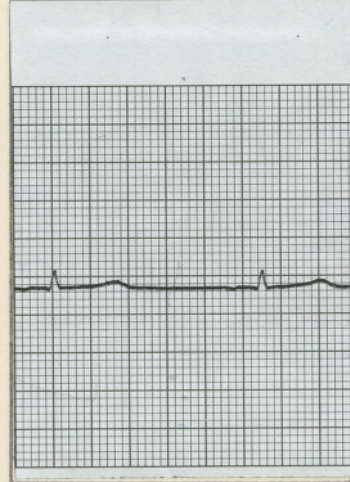
3



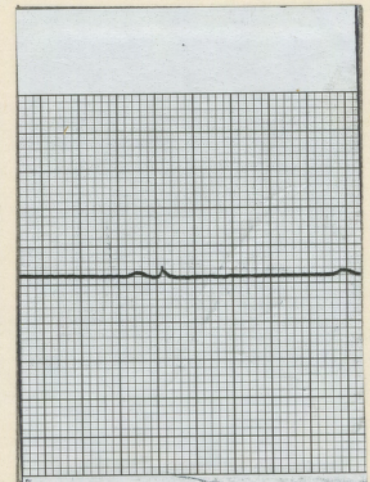
aVR



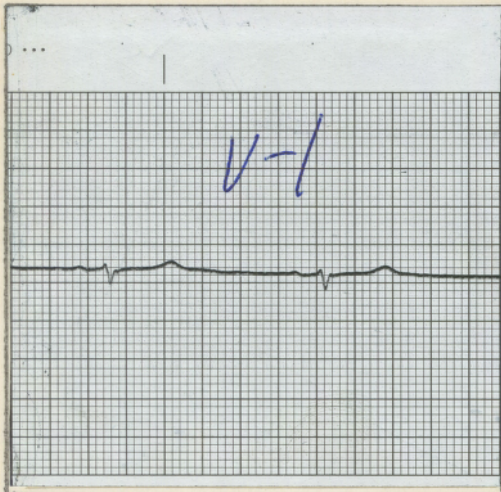
aVL



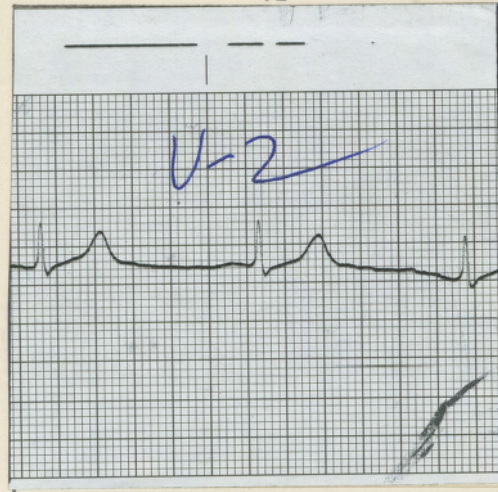
aVF



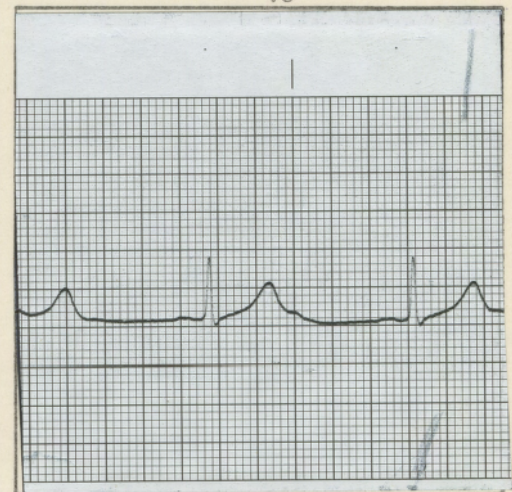
V1



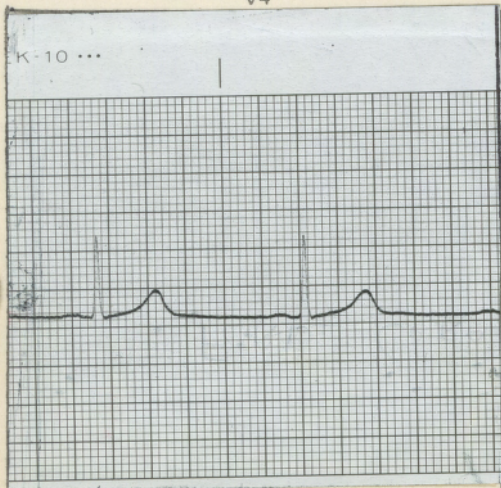
V2



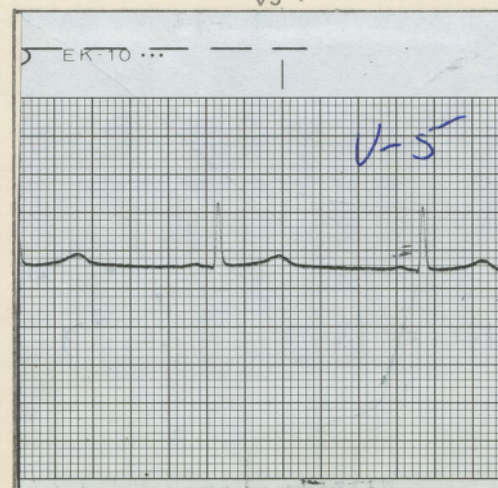
V3



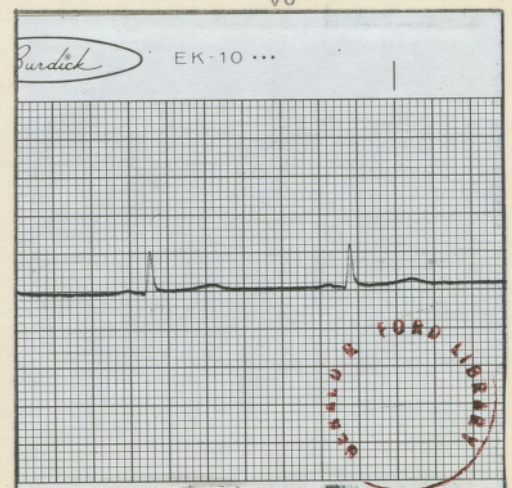
V4



V5



V6



LIBRARY  
OF THE  
HARVARD  
MEDICAL  
SCHOOL



NAME FORD, GERALD R. DATE 8/22/74 0700 CODE \_\_\_\_\_

ADDRESS \_\_\_\_\_

TEL. NO. \_\_\_\_\_ OCCUPATION \_\_\_\_\_

AGE \_\_\_\_\_ SEX \_\_\_\_\_ HT. \_\_\_\_\_ WT. \_\_\_\_\_ B.P. \_\_\_\_\_

PHYSICIAN W Lubish \_\_\_\_\_

HISTORY \_\_\_\_\_

DIGITALIS \_\_\_\_\_ QUINIDINE \_\_\_\_\_ OTHER \_\_\_\_\_ PAT. POS. \_\_\_\_\_

AURIC. RATE \_\_\_\_\_ P WAVES \_\_\_\_\_ Q-T INT. \_\_\_\_\_

VENT. RATE \_\_\_\_\_ P-R INT. \_\_\_\_\_ S-T SEG. \_\_\_\_\_

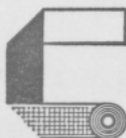RHYTHM \_\_\_\_\_ Q-R-S INT. \_\_\_\_\_ T WAVES \_\_\_\_\_

ELEC. AXIS \_\_\_\_\_

FINDINGS: no change from previous tracing in Jan. 74

REMARKS: normal ECG

CASE NO. \_\_\_\_\_ PATIENT \_\_\_\_\_ ECG \_\_\_\_\_ DATE \_\_\_\_\_



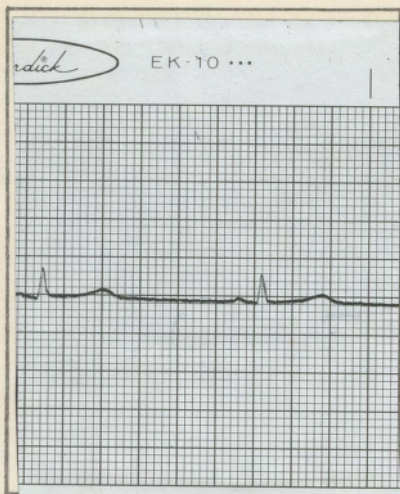
MADE IN U.S.A.  
BY

CARDIOGRAPHICS, INC.

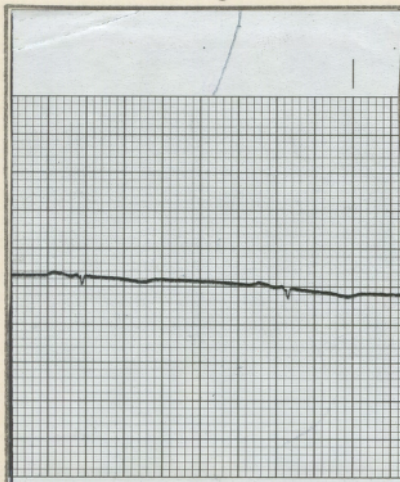
EKG MOUNTING CARD  
CATALOG #63-64



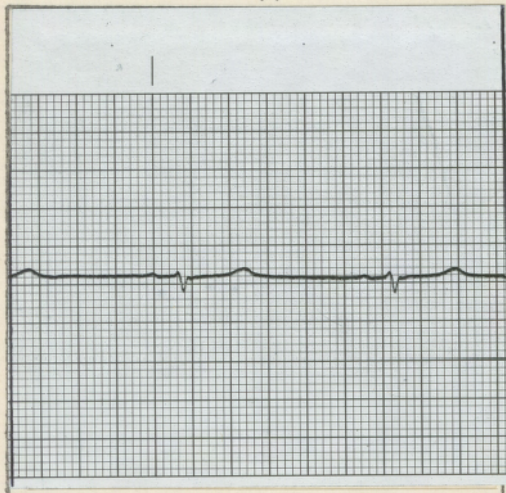
1



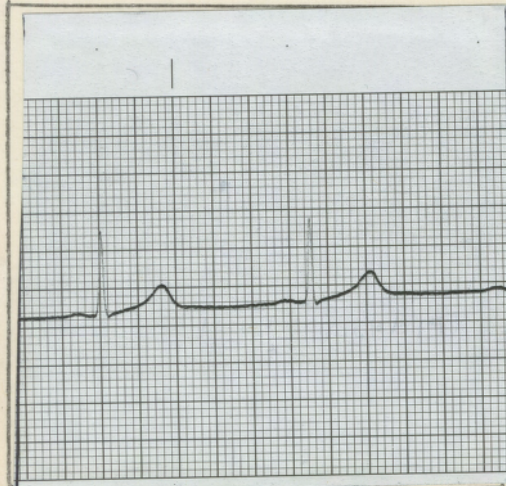
3



V1

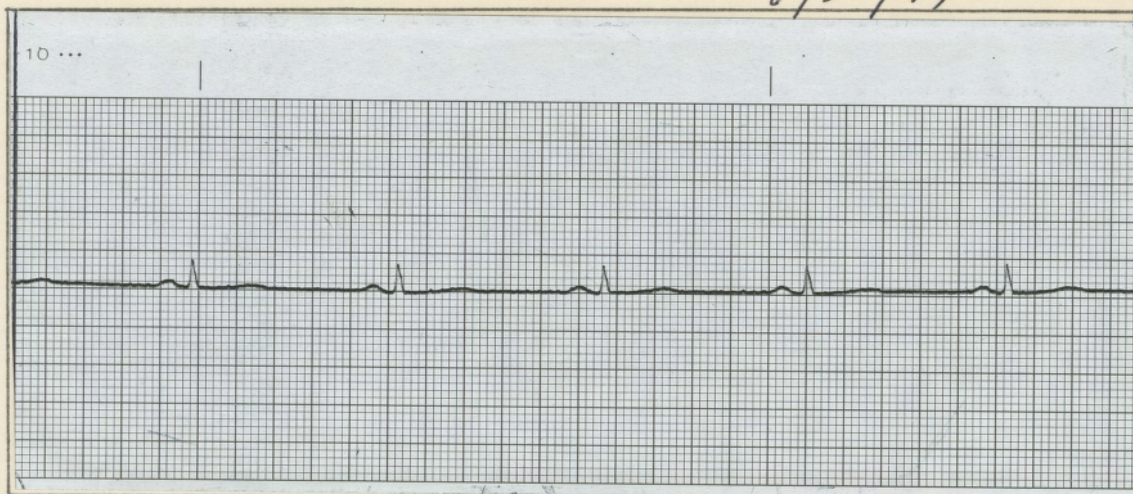


V4

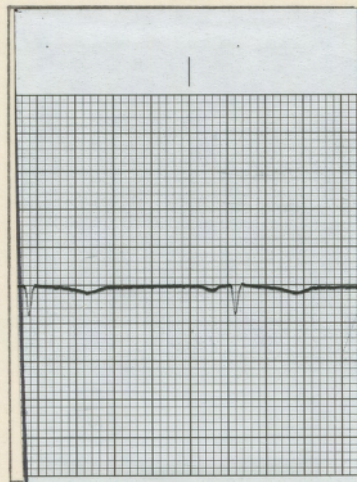


2

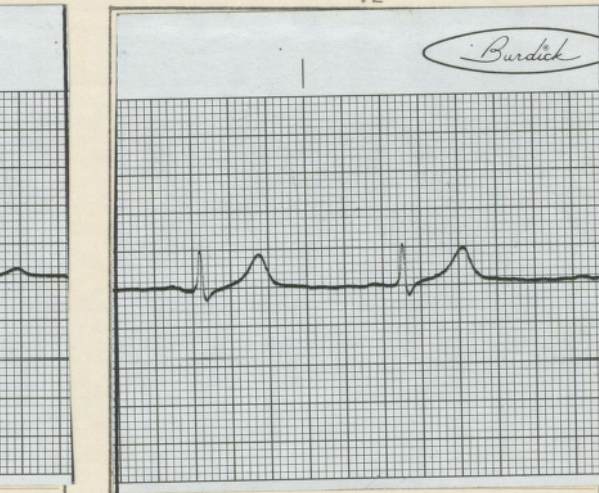
8/22/74



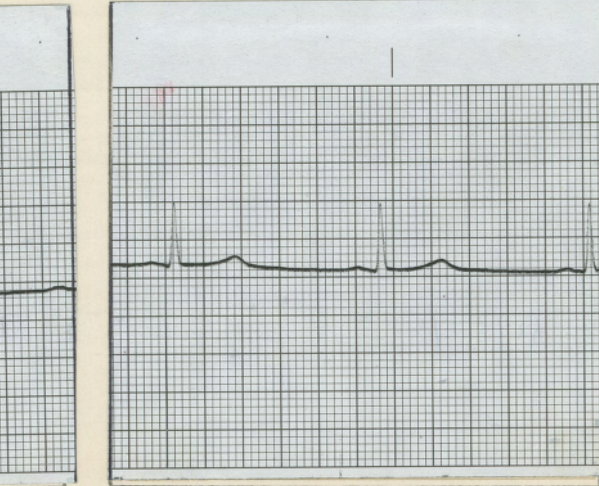
aVR



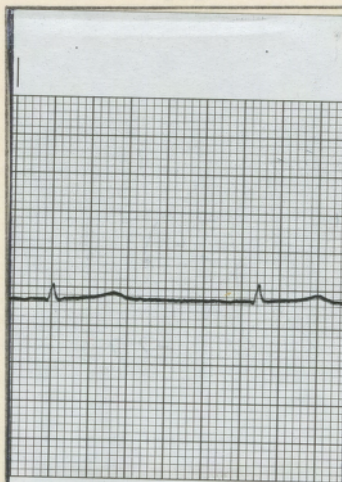
V2



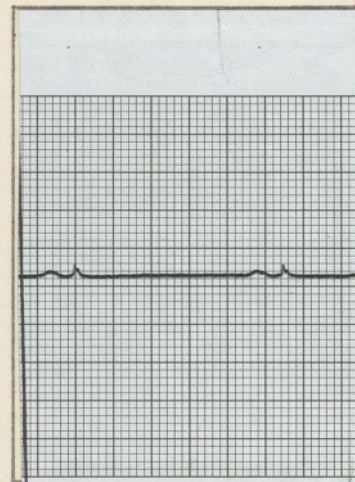
V5



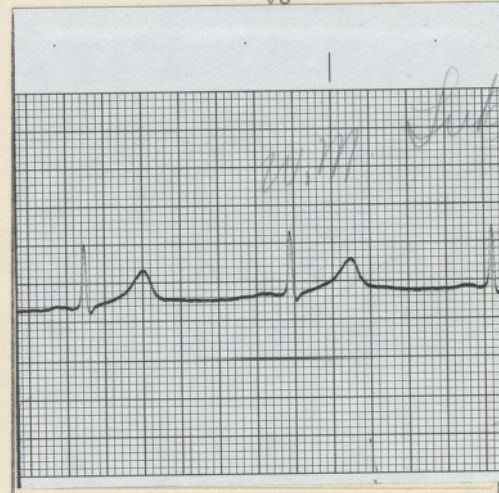
aVL



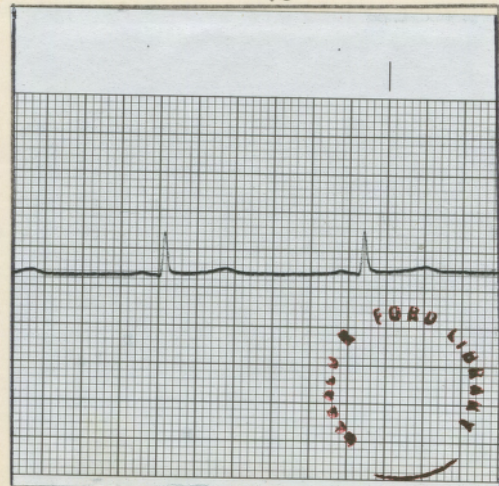
aVF



V3



V6





NAME FORD, GEROLD R. DATE 8/22/74 0700 CODE \_\_\_\_\_

ADDRESS \_\_\_\_\_

TEL. NO. \_\_\_\_\_ OCCUPATION \_\_\_\_\_

AGE \_\_\_\_\_ SEX \_\_\_\_\_ HT. \_\_\_\_\_ WT. \_\_\_\_\_ B.P. \_\_\_\_\_

PHYSICIAN \_\_\_\_\_

HISTORY \_\_\_\_\_

DIGITALIS \_\_\_\_\_ QUINIDINE \_\_\_\_\_ OTHER \_\_\_\_\_ PAT. POS. \_\_\_\_\_

AURIC. RATE \_\_\_\_\_ P WAVES \_\_\_\_\_ Q-T INT. \_\_\_\_\_

VENT. RATE \_\_\_\_\_ P-R INT. \_\_\_\_\_ S-T SEG. \_\_\_\_\_

RHYTHM \_\_\_\_\_ Q-R-S INT. \_\_\_\_\_ T WAVES \_\_\_\_\_

ELEC. AXIS \_\_\_\_\_

FINDINGS: normal

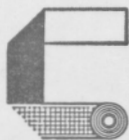REMARKS: no change from previous ECG in Jan 74

CASE NO. \_\_\_\_\_

PATIENT \_\_\_\_\_

ECG \_\_\_\_\_

DATE \_\_\_\_\_



MADE IN U.S.A.  
BY

CARDIOGRAPHICS, INC.

EKG MOUNTING CARD  
CATALOG #63-64

CLINICAL RECORD

LABORATORY REPORTS

ATTACH 3D REPORT ALONG HERE ↑ AND SUCCEEDING ONES ON ABOVE LINES

ATTACH 2D REPORT WITH TOP AT THIS LINE ↑

ATTACHING MARGIN

FORD, Gerald R.  
President of the United States  
The White House  
SSN: 372-28-6532

Enter in above space: PATIENT IDENTIFICATION—TREATING FACILITY—WARD NO.—DATE

REQUESTING PHYSICIAN'S SIGNATURE  
William M. Lukash, M.D.

REPORTED BY

MD

DATE

TECH

8/22/74

SPECIMEN/LAB. RPT. NO.

URIN-ALYSIS

URGENCY

☒ ROUTINE

TODAY ☐

☐ PRE-OP

STAT ☐

PATIENT STATUS

☐ BED ☒ AMB.

☐ OUTPATIENT ☐

☐ NP ☐ DOM.

SPECIMEN SOURCE

☐ ROUTINE

☐ OTHER (Specify)

LAB. ID. NO.

W.H.

REMARKS:

*Severe  
- negative casts  
Noted.*

TEST(D)	SPECIMEN TAKEN	DATE	TIME	AM	P.M.	REQUESTED	ROUTINE	COLOR	SPECIFIC GRAVITY	pH	GLUCOSE	PROTEIN	OCULT BLOOD	KETONES	MICROSCOPIC	WBC	RBC	EPH CELLS	WBC	RBC	HYALINE	GRANULAR	BACTERIA	CRYSTALS	MUCUS	BILE	URO-BILINOGEN	BENCE-JONES PROTEIN	HEMOGLOBIN	PSP	15 MIN.	1 HR.	HCG
		8/24	0700				<input checked="" type="checkbox"/>	5.0	1.020	5.0		NEG			<input checked="" type="checkbox"/>	4-6		few															

URINALYSIS

Standard Form 550 (July 1971) - GSA FPMR 101 - 11.8

PLATE NO. 14752

LABORATORY REPORTS

Standard Form 514

514-104

Stock No. 0109-201-2701

*Ford, President Gerald R.*



NAVAL MEDICAL SCHOOL  
NATIONAL NAVAL MEDICAL CENTER  
BETHESDA, MARYLAND 20014  
CLINICAL CHEMICAL DIVISION

PATIENT'S IDENTIFICATION FORD, Gerald R. The President of the United States The White House	AGE 61	SEX M	RACE Cauc.	I.D. NUMBER 372-28-6532
	REGISTER NUMBER			WARD

CLINICAL HISTORY				
PATIENT HISTORY:	BP 120/80	MI HX neg	ANGINA neg	DIABETES neg
THYROID STATUS normal	LIVER DISEASE			
ANTILIPEMIC THERAPY AND DOSAGE atorvastatin 1 g/dl (none the past wk)				
OBSIDITY 200 3/4 lbs	PREVIOUS STUDY not available			
MISCELLANEOUS slight elevation of cholesterol & triglyceride				

FAMILY HISTORY	
neg.	

PHYSICAL EXAMINATION		
XANTHOMAS none	TENDINOUS none	
PALMER none	ARCUS SENILIS none.	
DATE	REQUESTED BY	
	SIGNATURE W. M. Lusk RADM MC USN MC, USN	

LIPOPROTEIN ELECTROPHORETOGRAM			
CHEMISTRY:	SERUM:	CLEAR ✓	TURBID
TRYGLYCERIDES	165	MG %	CHOLESTEROL 260
GT			MG %

REMARKS
---------

Serum clear. Total and  $\beta$  cholesterol WNL. Total and pre- $\beta$  triglycerides WNL. Electrophoretic pattern not accurate when Lx has been instituted (non-baseline). Values are WNL for age

SIGNATURE \* (Interpretation based on assumption specimen is after 14 hour fast)

*[Signature]*



# THE HYPERLIPOPROTEINEMIAS

NORMAL	I	II	III	IV	V
Chylomicrons	↑↑↑	-	+ ↑	+ ↑	↑↑
Beta-Lipoproteins	+	↑↑↑	↑↑	+	↑↑
Pre-Beta Lipoproteins (α <sub>2</sub> )	+	+	↑↑	↑↑↑	↑↑
Alpha Lipoproteins	↓	+	+	+	↓
Cholesterol	↑ +	↑↑↑	↑↑	+ ↑	↑
Triglycerides 150 mgm %	↑↑↑	+ ↑	↑	↑↑	↑↑
Plasma	Milky	Clear	Turbid	Turbid	Turbid or milky
Induced by:	fat (exogenous)		CHO	CHO (endogenous)	CHO & fat
Detection age	<10y	<30y	adult	adult	adult
Xanthomas					
tendinous	o	++	+o	o	o
tuberous	o	++	+	o	o
eruptive	+	o	+	+	+
			(planar)		
Corneal Arci	o	+	+	o	o
Arteriosclerosis	o	++	+	o, +	o, +
Hyperuricemia	o	+	+	o	o
Abnormal G.T.T.	o	o	+	+	+
Hepatosplenomegaly	+	o	o	o, +	o, +
Abdominal pain	+	o	o	o	+
SECONDARY DISEASES					
diabetic ketoacidosis	+	o	o	+	+
pancreatitis	+	o	o	+	+
alcoholism	+	o	o	+	+
hypothyroidism	o	+	+	+	o
pregnancy	o	o	o	+	o
liver obstruction	o	+	o	o	o
nephrosis	o	+	+	+	o
dysglobulinemia	o	+	o	+	o

REMARKS

Serum clear. Total and  
 cholesterol was. Total  
 pre-B lipoproteins was  
 Electro phoretic pattern not accurate  
 when it has been water bathed (see  
 baseline). Values are wide for age.